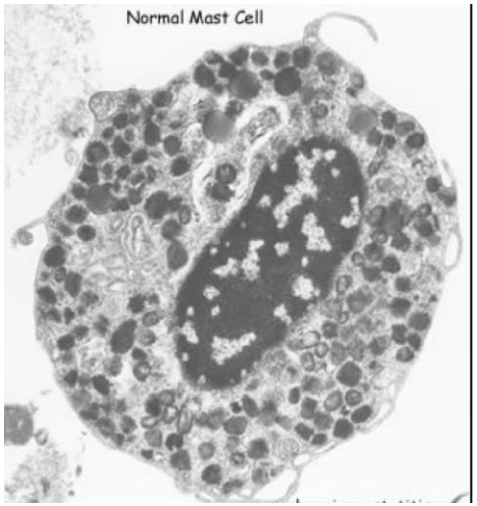

MAST CELL ACTIVATION SYNDROME

Anne Maitland, MD, PhD

Asst. Professor,
Otolaryngology and Medicine
Icahn School of Medicine at Mount Sinai

Medical Director,
Comprehensive Allergy & Asthma Care
Mast Cell Activation Center of New York

MAST CELLS GO WILD

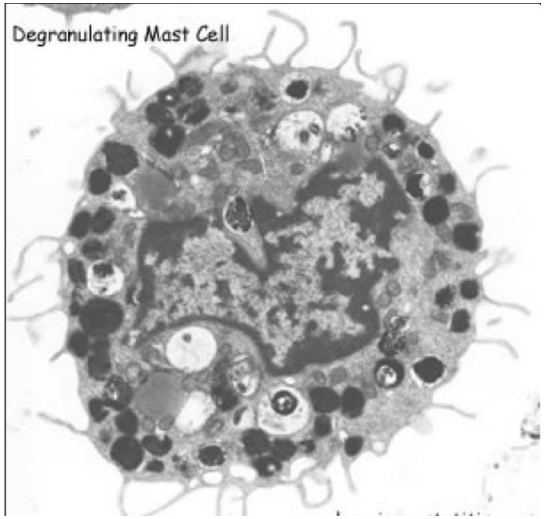

First Signs….

- Since birth… rash, pain, severe allergic reactions
- Negative “allergy tests” to foods
- Also with fatigue, pain, rhinitis, asthma
- Symptoms controlled with diet (6 foods) and environment modifications

Toddler with rashes, colic, asthma, anaphylaxis

- 10 allergists, 4 gastroenterologists, 4 orthopedists, 3 geneticists, 2 rheumatologists, 2 endocrinologists, 2 nutritionists, 2 physical therapists, a cardiologist, neurologist, and pulmonologist (2008 -2011)
- “My son's "complex case" often leaves doctors bewildered or in disbelief, Only recently have we stumbled upon a doctor who is open minded and dedicated to helping us find answers”.

Was fine until…



- 19 year old student athlete with longstanding “allergies”
- Last November, suffered a “stomach bug”
- Started losing weight, even after restricting diet
- Increased vomiting around her menses
- Evaluation and testing with endocrinologists, primary care, gastroenterologists, allergy/immunology specialists- unknown etiology

Mast cell activation syndrome: A newly recognized disorder with systemic clinical manifestations

Matthew J. Hamilton, MD,[a] Jason L. Hornick, MD, PhD,[b] Cem Akin, MD, PhD,[a] Mariana C. Castells, MD, PhD,[a] and Norton J. Greenberger, MD[a] *Boston, Mass*

Mast Cell Activation Disorders On the Rise

By Mark L. Fuerst
Reviewed By Miriam K. Anand, MD, FAAAAI, FACAAI, Clinical Associate Professor, Arizona College of Osteopathic Medicine, Midwestern University; President, Allergy Associates & Asthma, Tempe, Arizona

Increasing numbers of patients and their physicians are learning that they have mast cell activation (MCA) that is not associated with mastocytosis or with a defined allergic or inflammatory reaction.

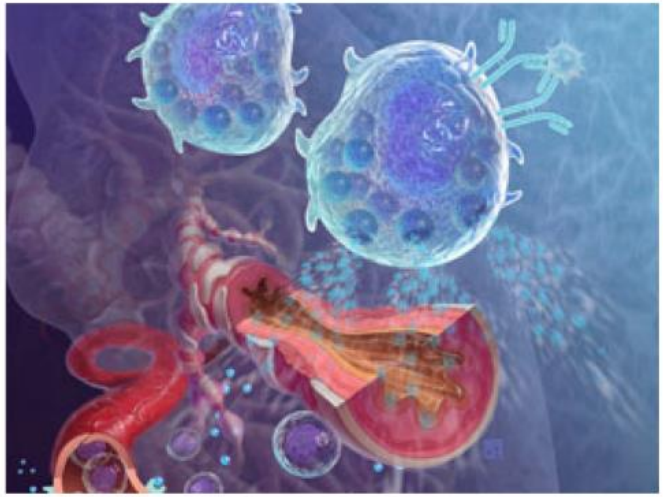

Three types of MCA syndromes (MCAS) have been defined, including primary MCAS, secondary MCAS, and idiopathic MCAS. The criteria to define MCAS include:

Typical clinical symptoms

Mast Cells?

Proteins and cells of the Immune System = Defense

Defense Cells & Proteins of the Innate Immune System

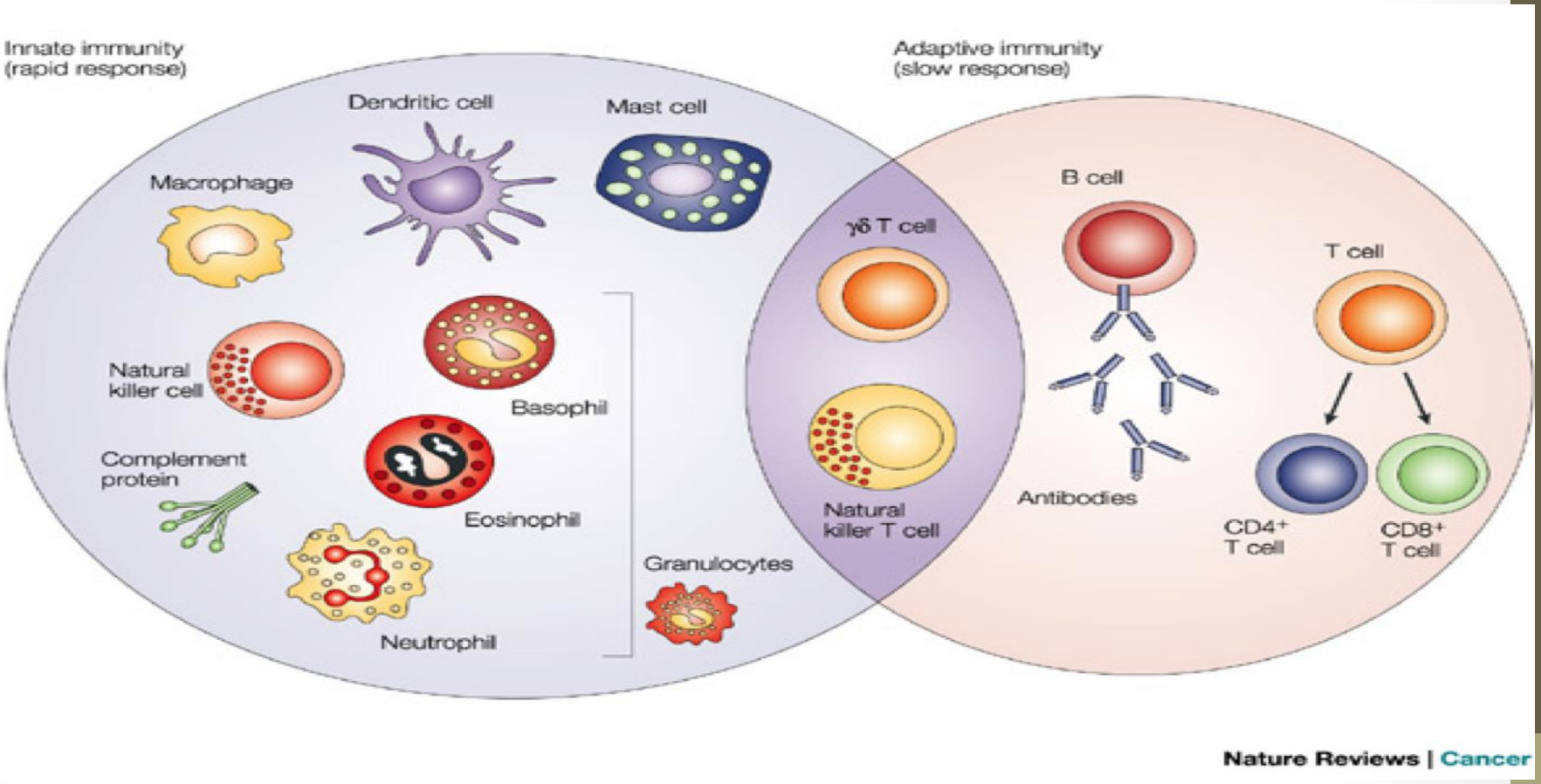

"The First Responders" = React with seconds to minutes to danger
Innate receptors have no memory, recognize Invariant Pathogen Associated Molecular Patterns (PAMPs)

Mast Cell Development

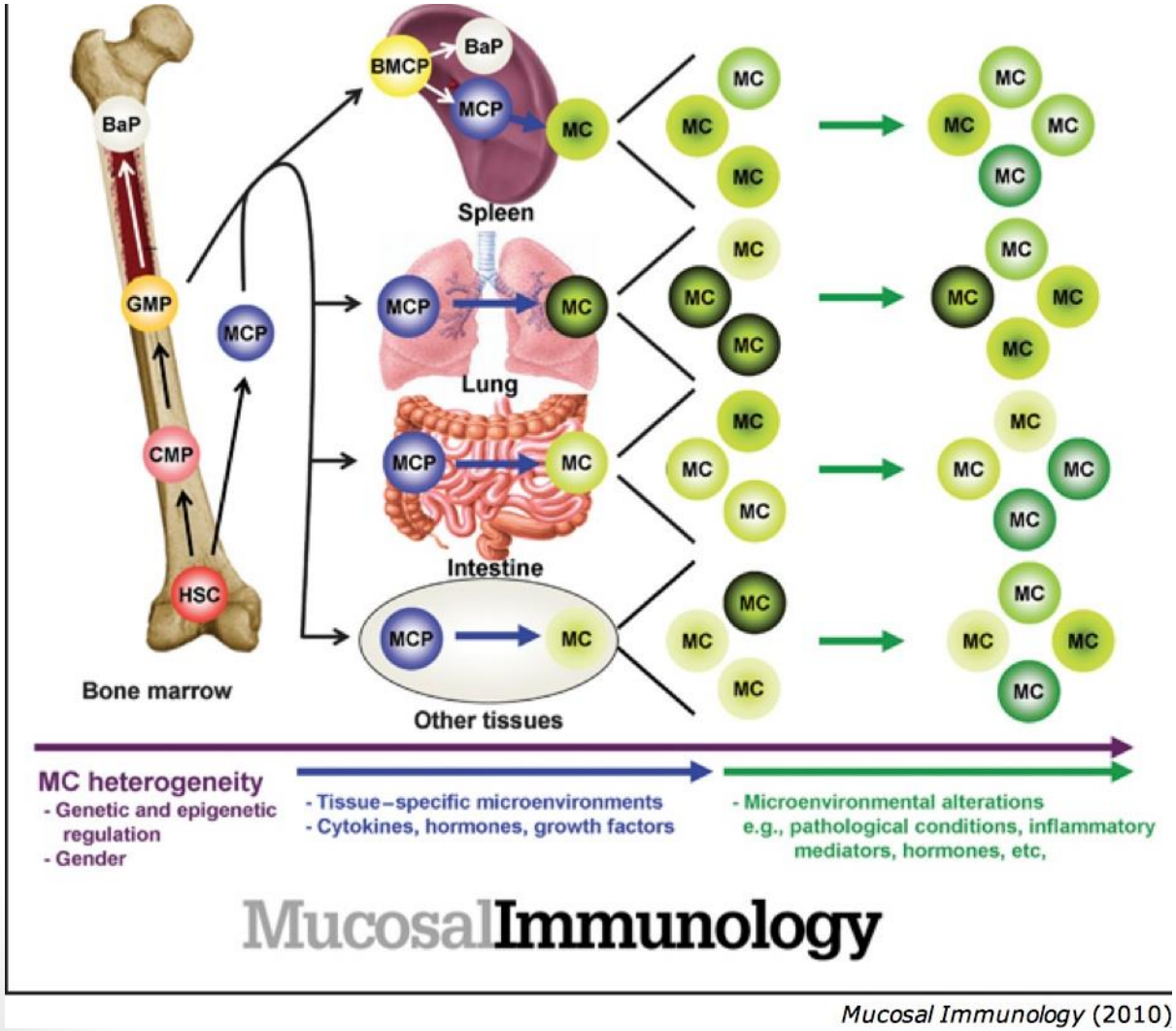

Mucosal Immunology (2010)

(1) Mast Cells: Precursors in the bone marrow

↓

Blood Stream

↓

*Homing to tissues – Gut, Skin, Respiratory Tract
*Granule Production
*Local Survival

Common Mast Cell Triggers
Allergic (IGE) & Non-Allergic (not IGE)

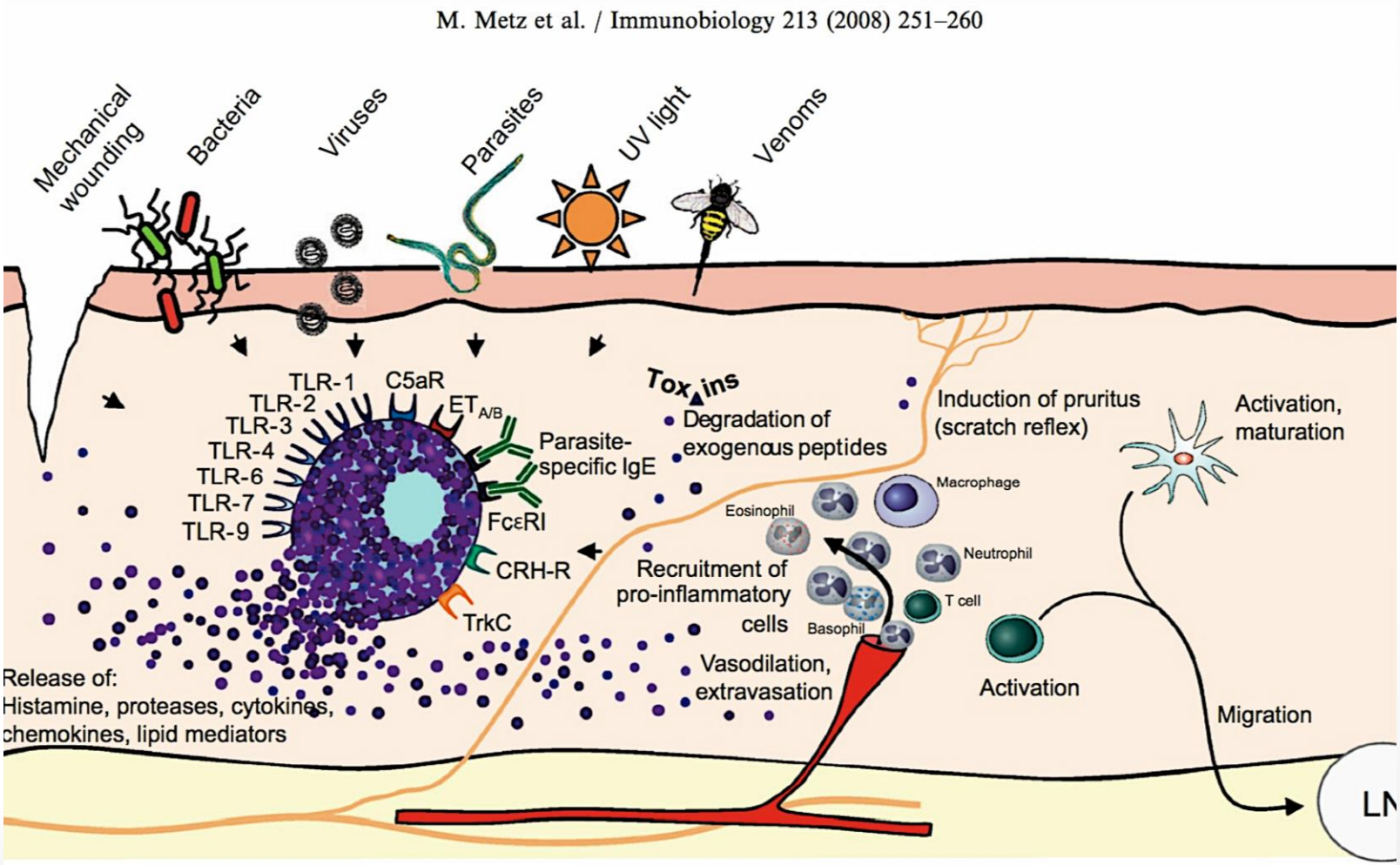

Age of Immune Dysregulated Diseases

20th Century = Increased Burden of Autoimmune and Allergic Diseases

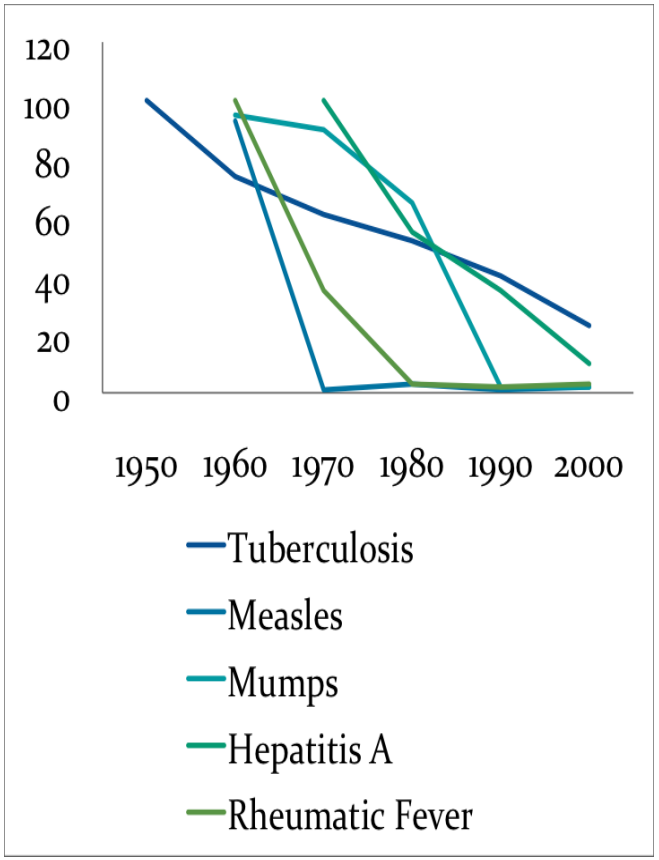

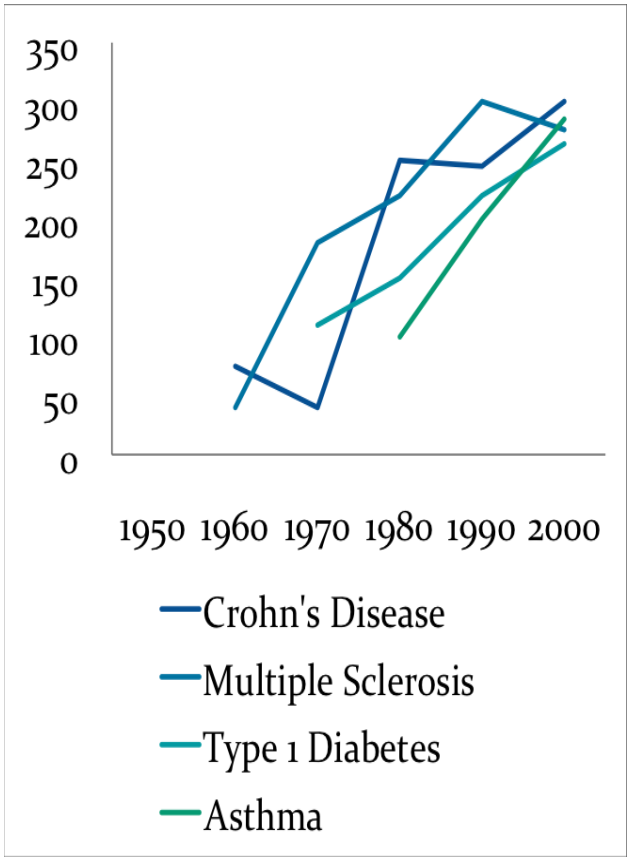

Adapted from Bach, NEJM 2002

Mast Cell Activation Disorders

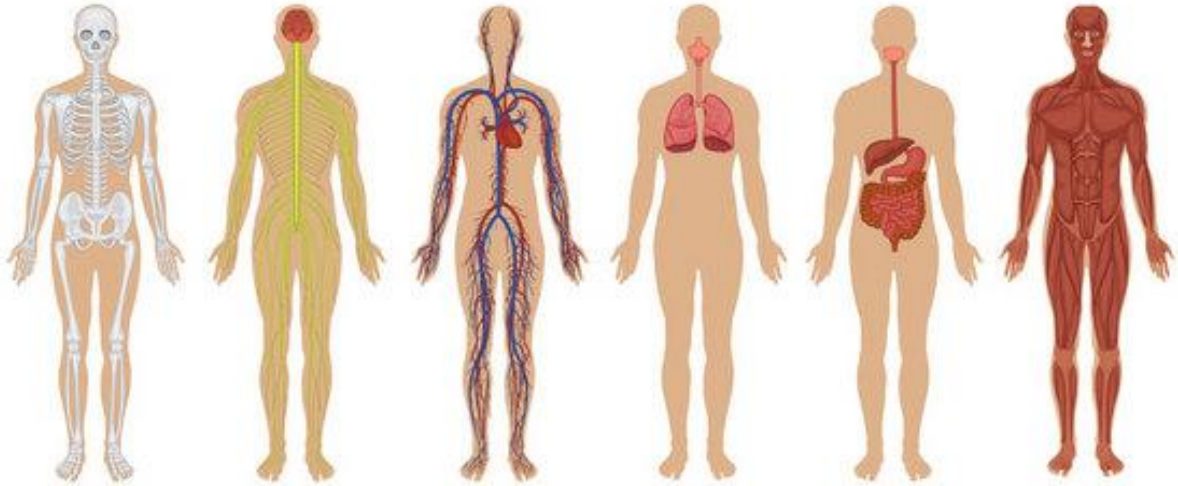

- Mast Cell (MC) Disorders can affect any organ system, particularly
  - Gastrointestinal tract, Skin, Respiratory Tract
  - MC also have been found in joints, uterus
- Disorders can results from
  - Increased proliferation (mastocytosis, monoclonal MCAS)
  - Increased Activity (nonclonal, overactive Mast Cells)

"Allergies"/Allergic Disorders on the Rise:
Rhinitis (Nose Problems), Urticaria (Hives), Angioedema (Swelling), Asthma, Anaphylaxis



Allergic Rhinitis / Sinusitis/ Conjunctivitis

Food induced Anaphylaxis

Urticaria / Angioedema

Asthma



“Allergies”
Find IgE that recognizes harmless ingested, airborne, or contact allergen

Allergic (IGE) Mast Cell Triggers

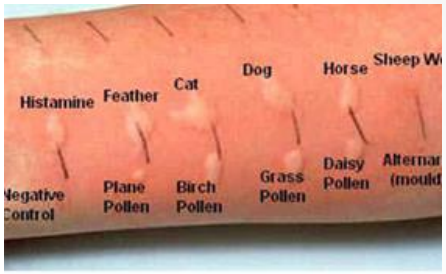

Skin Allergy Test

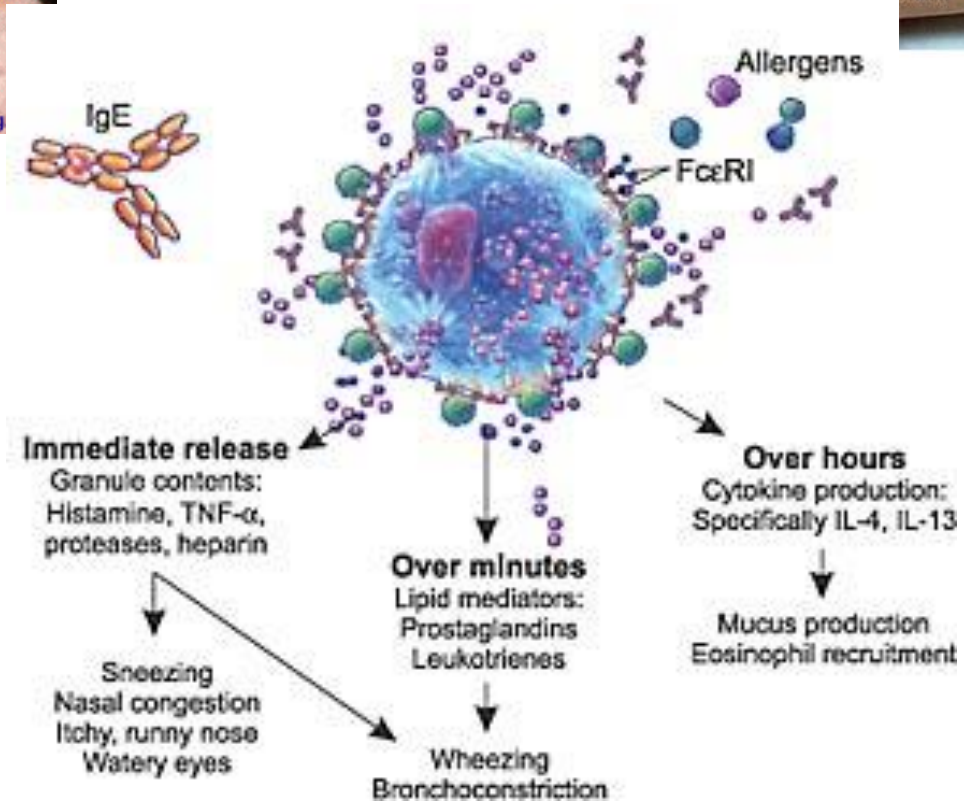

Detected IGE to
Airborne
Food
Drugs
Insects
Chemicals

Non-IGE mediated Mast Cell Triggers

IGG-Antigen Complexes / Autoimmune IGG

Infections

Physical Triggers
Vibration
Heat
Cold
Solar
Cholinergic

Insect Stings

Medications
Aspirin
Opoids
Antibiotics
Anesthesia

Coagulation Cascade

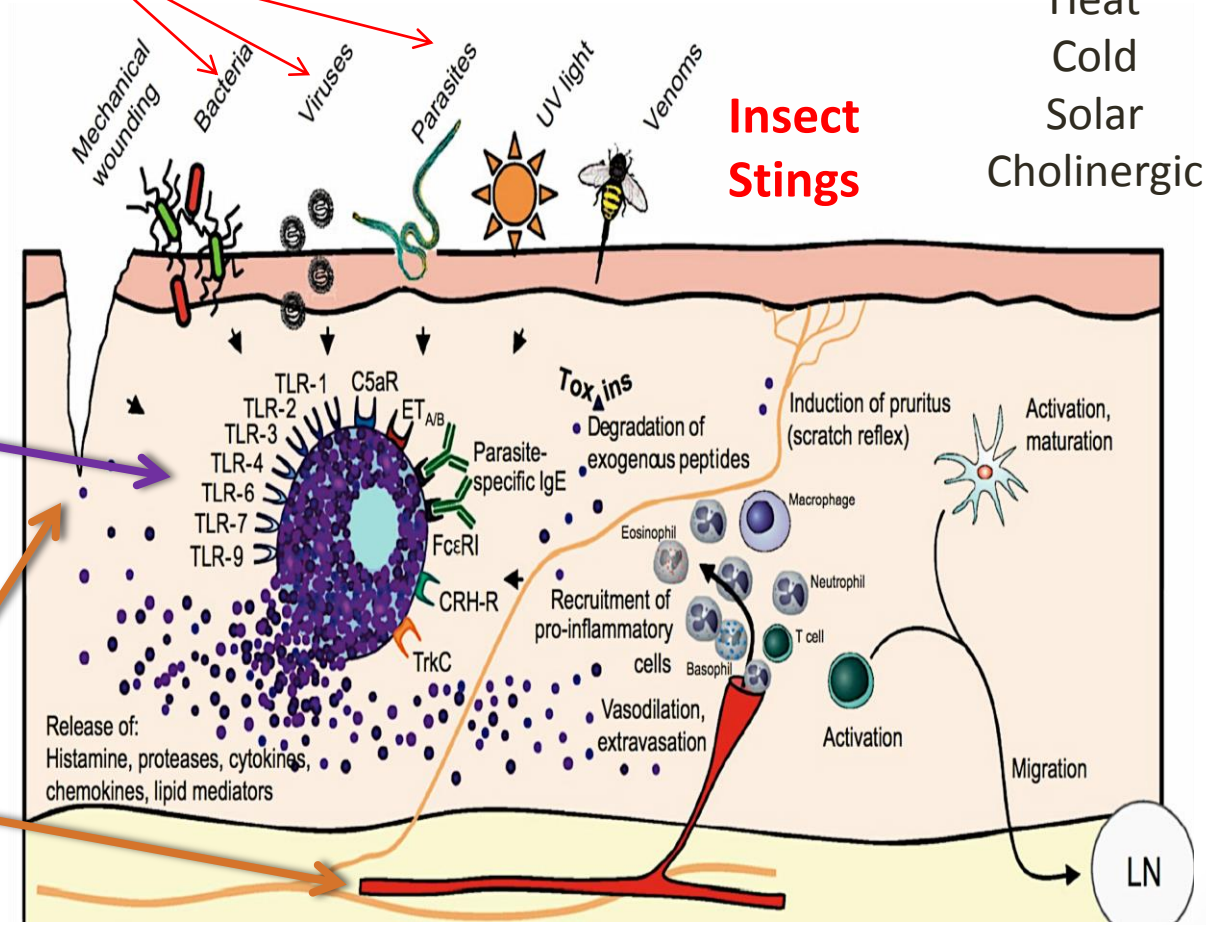

“Allergic” =
Allergen-Specific IGE

“Non-Allergic” =
Cannot find
Allergen-Specific IGE

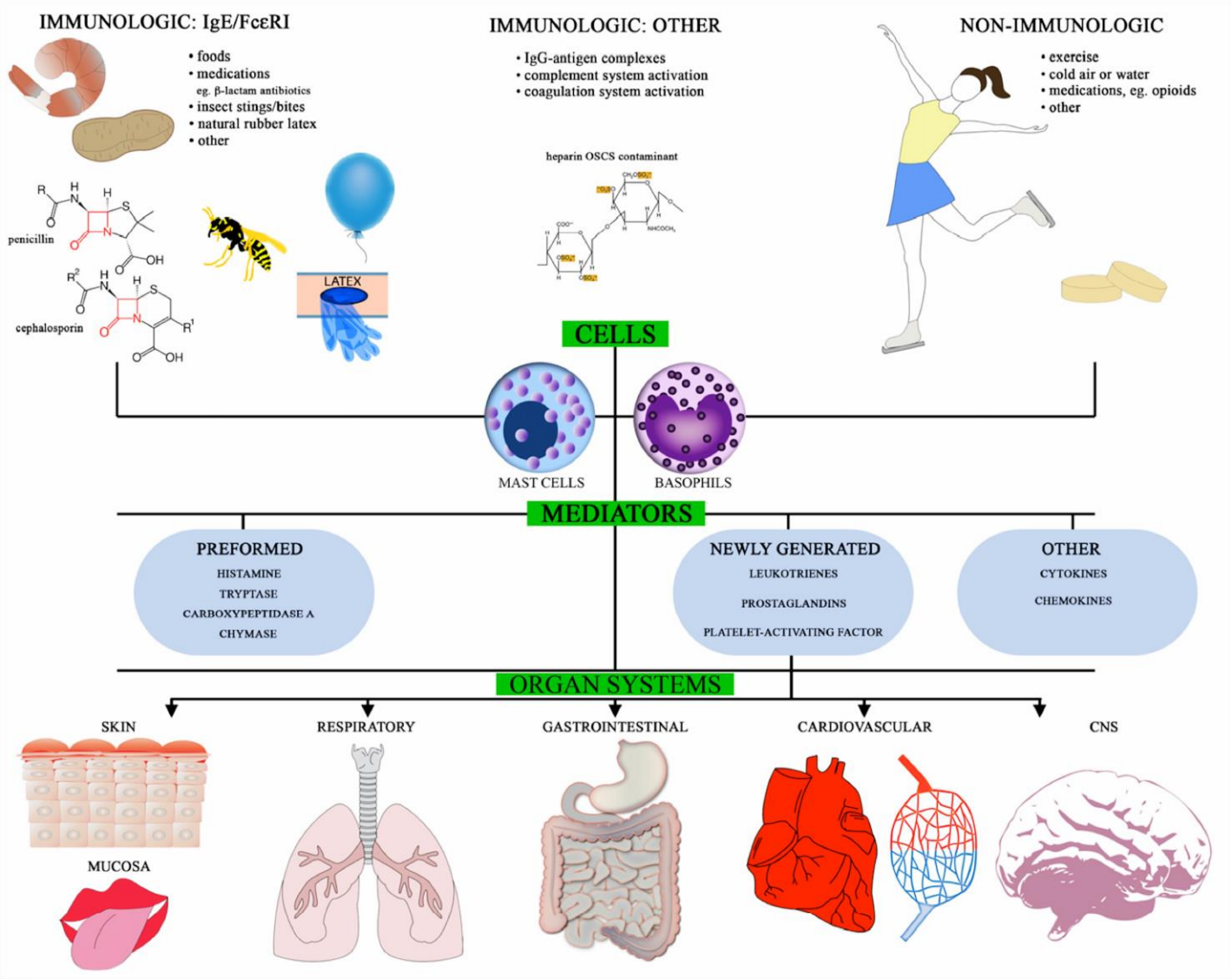

Simons et al, JACI 2009

Anaphylaxis/MCAS-Signs & Symptoms

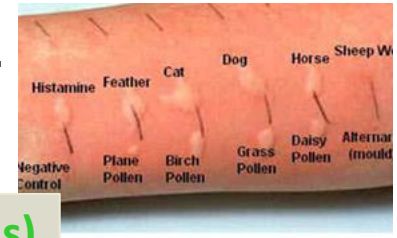

Skin Allergy Test

Skin (80-90% reactions)
Hives (urticaria)
Itch
Flushing
Mucosa
Itch, swelling –
lips, tongue, mouth)

Brain
(> 20% reactions)
Sense of uneasiness
Headache
Dizziness
Confusion
Tunnel Vision

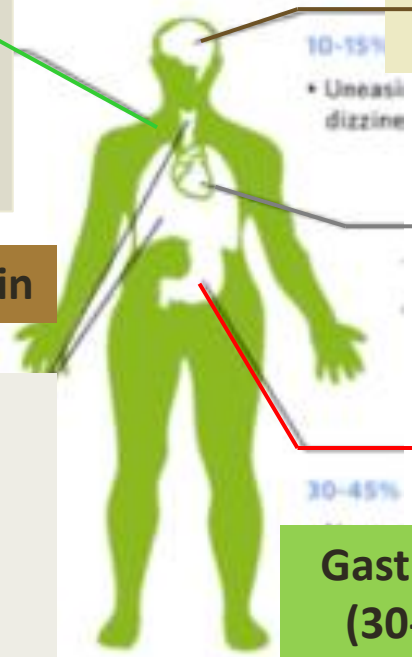

Joint/Muscle Pain

Heart, Blood Pressure
(10-45 % reactions)
Chest Pain
Fast Heart Rate,
Palpitations (pounding)
Weak pulse
Dizziness
Fainting

Airway (70% reactions)
Throat Tightening, swelling
Lungs = chest tightness,
wheeze,
can't take a deep breath

Gastrointestinal tract
(30-45% reactions)
Nausea
Cramping
Abdominal Pain
Vomiting
Diarrhea

Genito-Urinary tract
(>10% reactions)
Uterine Cramping
Swelling -labia

Mast cell activation syndrome is easily treated, if it's recognized

Hamilton, Reuters 2013

Patients with mast cell activation syndrome (MCAS) frequently go for years without an accurate diagnosis, but once diagnosed and treated, their response is likely to be "excellent”….

Mast Cell Activation Syndrome (MCAS): a collection of disorders characterized by…

Resting mast cell

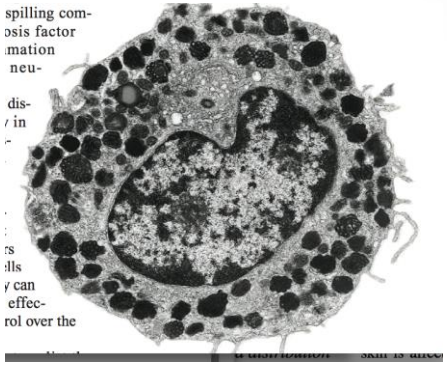

- **Accumulation** of pathological mast cells in potentially any or all organs and tissues

- **Aberrant** release of variable subsets of mast cell mediators, leading to one of more symptoms (suggestive of systemic mast cell degranulation)

Activated mast cell

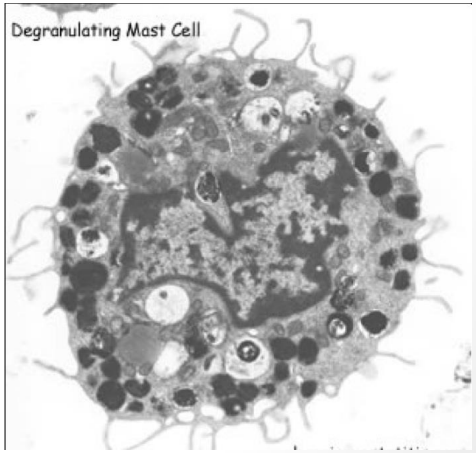

Got MCAS?

Diagnosis of Mast Activation Disorders/Syndrome

(1) Signs and Symptoms worrisome for MCAS

(2) Respond to medications that target Mast Cells

(3) Data supporting Mast Cell Activation

(4) Ruled out other syndromes that can cause similar symptoms

(5) Clonal vs Nonclonal Mast Cell Activation Disorders

	Classification of MCAS – Mast Cell Activation Disorders
Primary	Symptoms Associated with monoclonal mast cell population A. Mastocytosis B. Monoclonal Mast Cell Activation Syndrome (MMAS)
Secondary	**A. Allergic (IGE mediated) Disorders** B. Mast Cell activation associated with chronic inflammatory (Primary Immunodeficiency) or Neoplastic disorders C. Physical Urticaria (*Connective Tissue Disorders??*) D. Chronic Autoimmune Urticaria
Idiopathic	A. Anaphylaxis B. Angioedema C. Urticaria D. MCAS

Clonal Mast Cell Activation Disorder:
Signs and Symptoms

- Mastocytosis
- Monoclonal Mast Cell Activation Disorder
  - (Escribano et al, JACI 124:514)

Skin Lesions	90%
Pruritis	82%
Flushing	56%
Diarrhea	35%
Abdominal Cramping	30%
Neuropsychiatric Symptoms	23%
Anaphylaxis	23%
Peptic Symptoms	20%
Osteoporosis	18%
Hepatomegaly	12%
Splenomegaly	8%

Non-Clonal
Mast Cell Activation Disorder:
Signs and Symptoms

Abdominal Pain	94%
Dermatographism	89%
Flushing	89%
Headache	83%
Neuropsychiatric	67%
Diarrhea	67%
Rhinitis (Naso-ocular)	39%
Asthma	39%
Anaphylaxis	17%

Mast cell activation disorder

Hamilton, jaci 128;147

(2) Measuring Mast Cell Activation: Activation Markers, Inflammatory Mediators

Pathology- spindle MC, MC aggregates

IgE

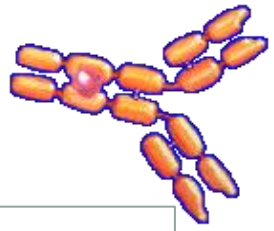

CD2, CD25 CD30

Urine Histamine, PGD2, 11-beta PGF2

Allergens

FcεRI

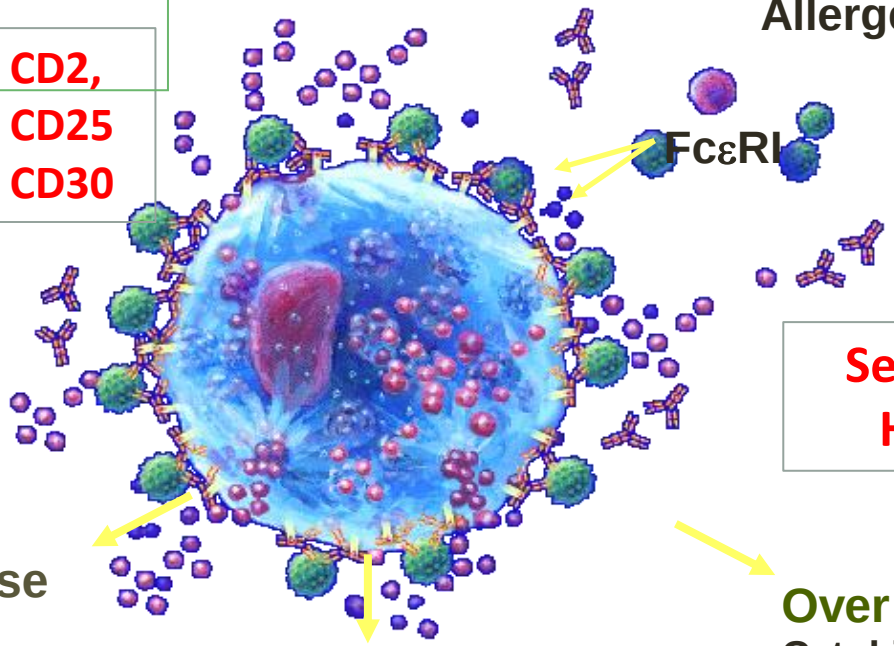

Serum Tryptase

Serum, Urine Histamine

Immediate Release

Granule contents:
Histamine, TNF-α,
Proteases, Heparin

Sneezing
Nasal congestion
Itchy, runny nose
Watery eyes

Over Minutes

Lipid mediators:
Prostaglandins
Leukotrienes

Wheezing
Bronchoconstriction

Over Hours

Cytokine production:
Specifically IL-4, IL-13

Mucus production
Eosinophil recruitment

(3) Response to Treatment: Targeting MC/MC Inflammatory Mediators

Anti-IGE mAb

IgE

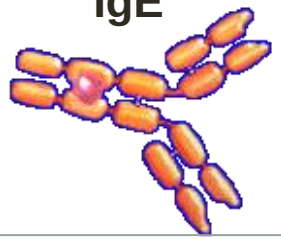

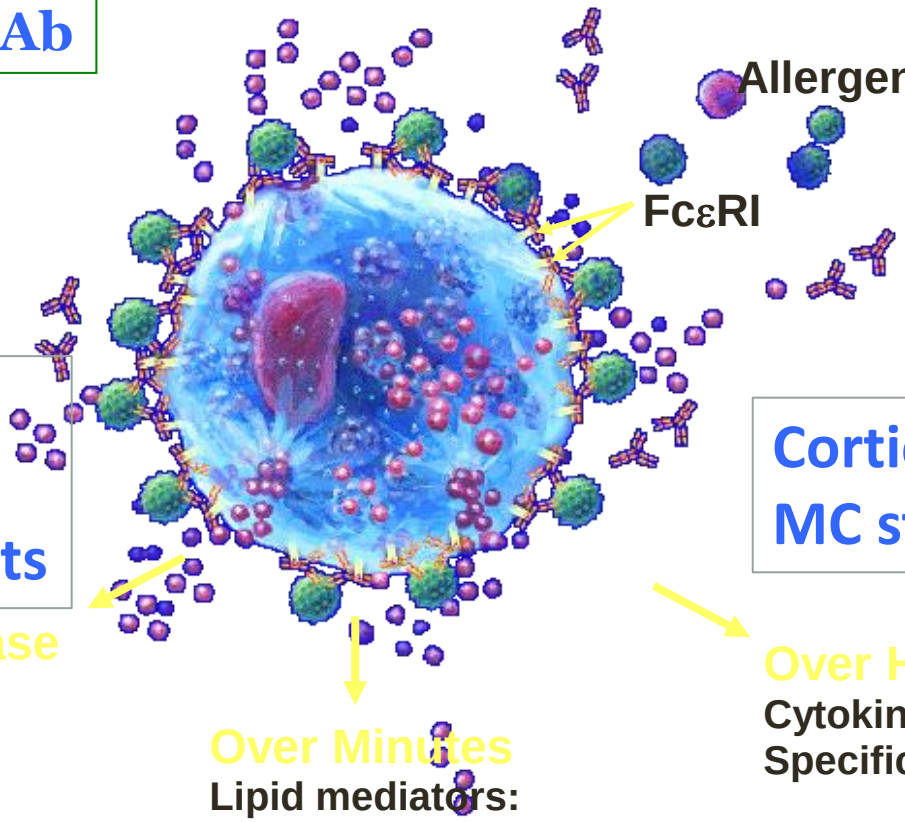

TCM= Traditional Chinese Herbal Medicine

Histamine Blockers, Tricyclic Agents

Corticosteroids MC stabilizers

Immediate Release

Granule contents:
Histamine, TNF-α,
Proteases, Heparin

Sneezing
Nasal congestion
Itchy, runny nose
Watery eyes

Over Minutes

Lipid mediators:
Prostaglandins
Leukotrienes

Wheezing
Bronchoconstriction

Over Hours

Cytokine production:
Specifically IL-4, IL-13

Mucus production
Eosinophil recruitment

Leukotriene Blockade

Inherited Connective Tissue Disorders

Ehlers-Danlos syndrome (EDS) is a heterogeneous group of inherited connective tissue disorders Castori, 2012

Subtype	Inheritance AD AR XLD	Gene (s)
Classic Skin extensibility, Jt hypermobility	AD	COL5A1 COL5A2
Hypermobility/JHS	AD???	Mostly unknown
Vascular	AD	COL3A1
Kypho-scoliotic	AR	PLOD1
Arthrochalasia	AD	COL1A1, COL1A2
Dermatosparaxis	AR	ADAMTS2

- Group of inherited connective tissue disorders caused by defect in collagen synthesis,
  - structural proteins or
  - proteins/enzymes involved with collagen 1 biogenesis
- EDS subtypes can be diagnosed clinically or genetically

Of the Six Ehlers Danlos Subtypes, Joint Hypermobility Syndrome is the Most Common

EDS- Hypermobility Syndrome = a hereditary condition wit predominant rheumatologic manifestations…

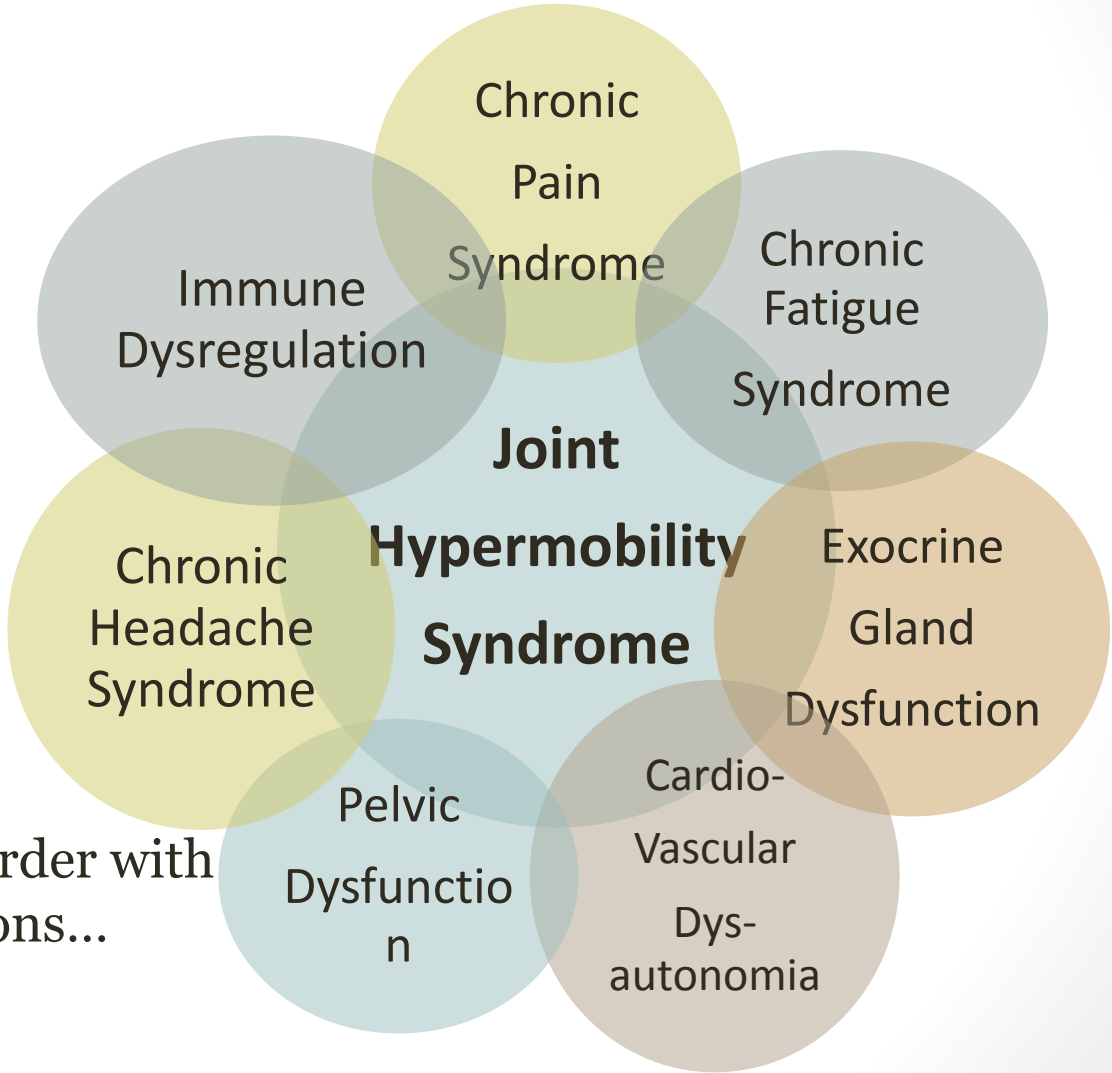

It is now emerging as a multi-systemic disorder with widespread manifestations…

Castori, Dermatology 2012

EDS- Hypermobility Syndrome = a hereditary condition, with widespread, multi-systemic disorder

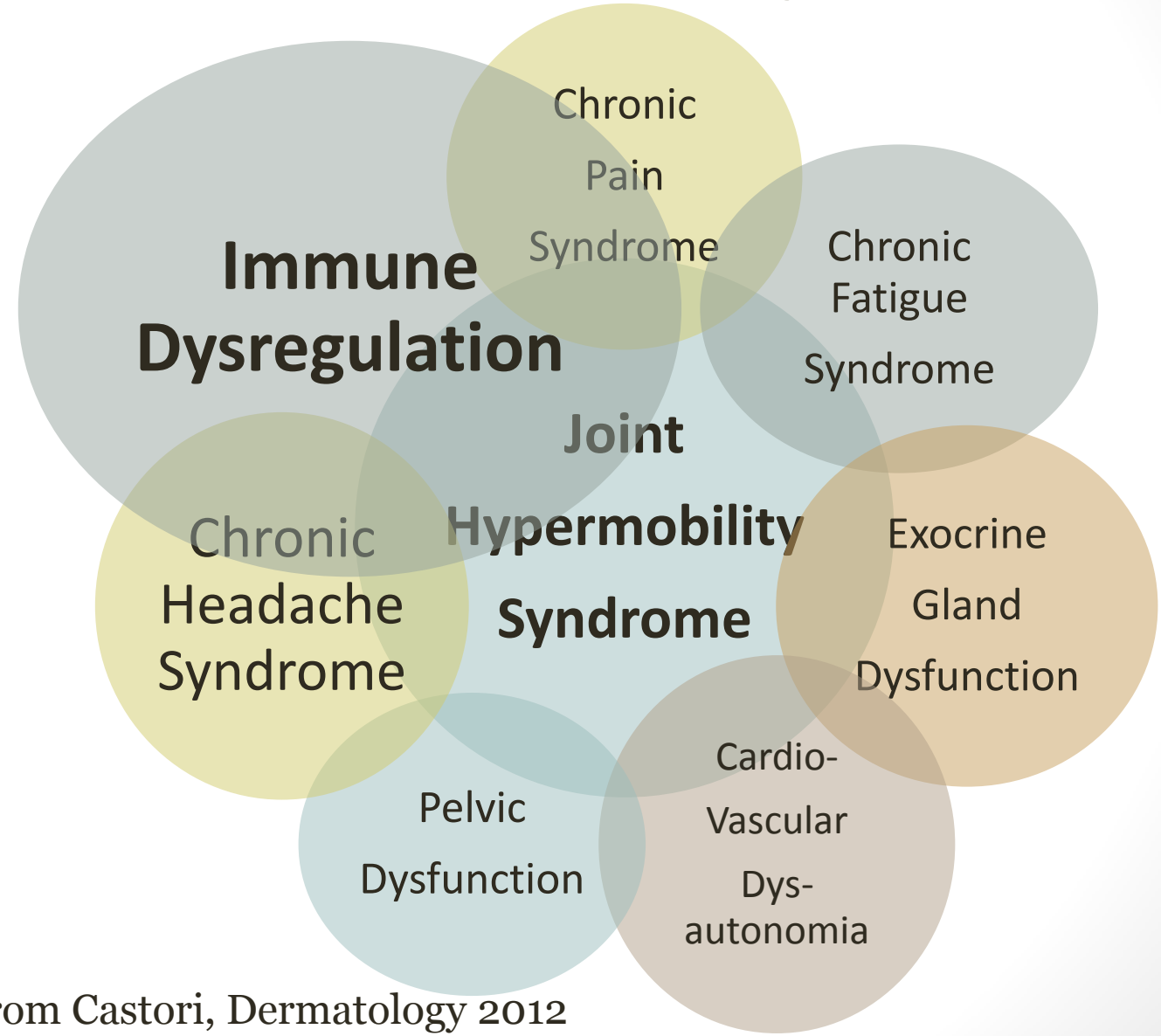

Adapted from Castori, Dermatology 2012

EDS- Hypermobility Syndrome & MCAS

Subtype	Inheritance AD AR XLD	Gene (s)
Classic Skin extensibility, Jt hypermobility	AD	COL5A1 COL5A2
Hypermobility/ JHS	**AD???**	**Mostly unknown**
Vascular	AD	COL3A1
Kypho-scoliotic	AR	PLOD1
Arthrochalasia	AD	COL1A1, COL1A2
Dermatosparaxis	AR	ADAMTS2

- All patients had EDS-HJS confirmed by a geneticist, physiatrist or rheumatologist
- 6 adults, 31 to 53 years of age
- 3 children, 5 to 9 years
- 67% female (6 patients)

EDS-JHT: Meeting the Proposed Criteria for MCAS Diagnosis?

- (1) Episodic Symptoms Consistent with Mast Cell (MC) Activation
  - **9 of 9 patients = skin, GI, CV, respiratory**

- (2) Response to therapy – decrease in frequency, severity or resolution of symptoms with anti-MC mediator therapies or MC stabilizers
  - **All 9 patients needed at least 2 classes of anti-MC therapies to control symptoms, and**
  - **7 of 9 required rescue B-agonist therapy for acute respiratory or CV distress (albuterol, epinephrine)**

Case Series: Meeting the Proposed Criteria for MCAS Diagnosis?

- (3) Evidence of an increase in validated urinary or serum markers of MC activation
  - **In NY state, only serum tryptase and 24 hr urine histamine are available, all 9 patients had serum tryptase < 10 IU/ml**

    Decreased likelihood MMAS, SM or MCL by bone marrow MC aggregates diminishes significantly in those with tryptase < 20 ng/mL (Akin et al, 2011)
  - 24 hour urine collection to measure prostaglandin D2 (not available in NY state)

Case Series: Meeting the Proposed Criteria for MCAS Diagnosis?

- (4) Rule out Primary and Secondary Causes of MC activation, established clinical entities that trigger or mimic MC activation
  - Patients often undergo multiple medical evaluations by different physicians without a definitive diagnosis.

EDS-JHS patients = Secondary MCAS

Primary	Symptoms Associated with monoclonal mast cell population A. Mastocytosis B. Monoclonal Mast Cell Activation Syndrome (MMAS)
Secondary	A. Allergic (IGE mediated) Disorders B. Mast Cell activation associated with chronic inflammatory or Neoplastic disorders **C. Physical Urticarias/Systemic Hypersensitivity Reactions = Inherited Connective Tissue Disorders** D. Chronic Autoimmune Urticaria
Idiopathic	A. Anaphylaxis B. Angioedema C. Urticaria D. MCAS

Mast Cells and the Mucosa

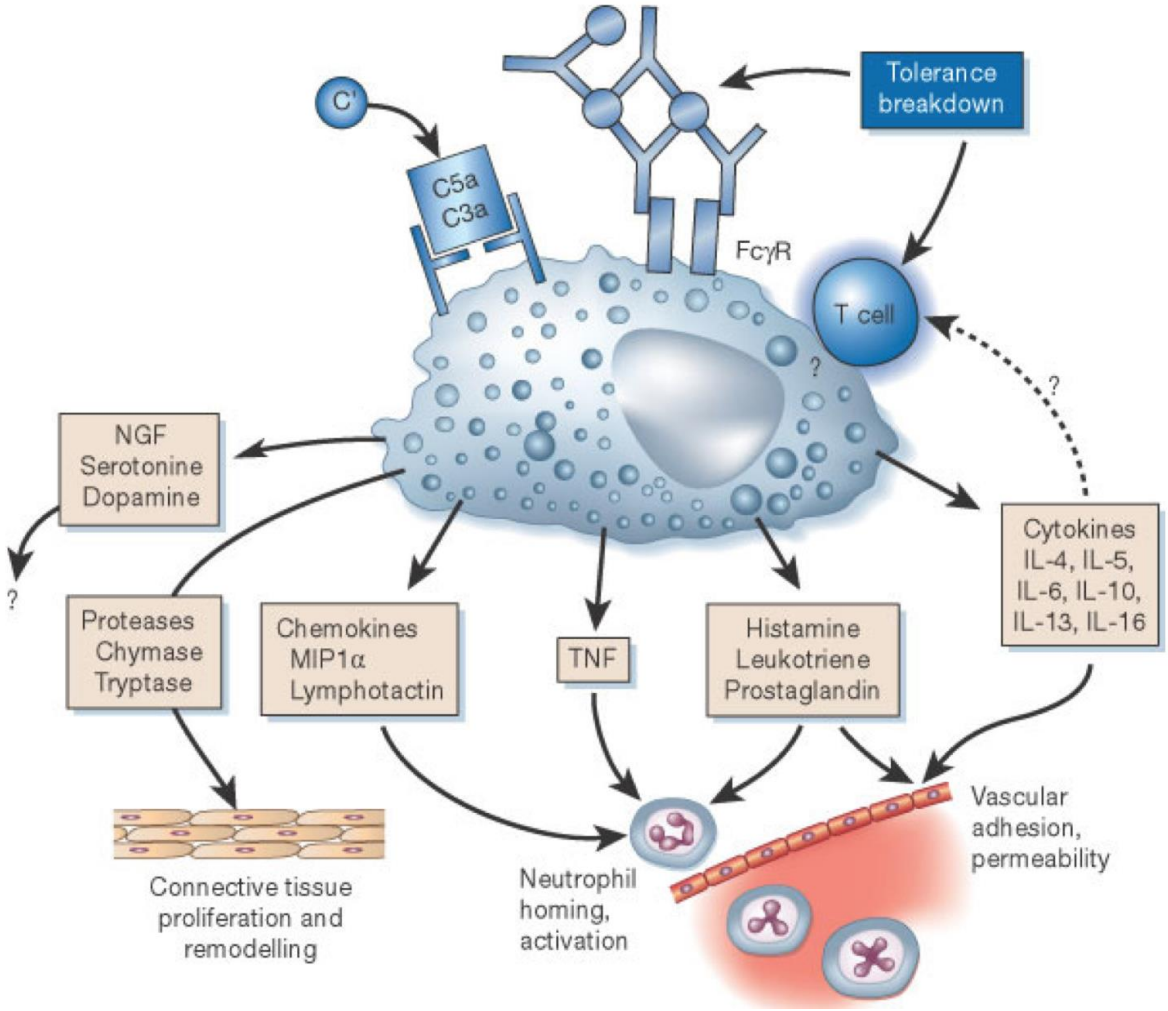

Why the delay in diagnosis?

Allergic disease now cause problems of increased complexity and commonly involves several organ systems, so patients are often referred to a succession of different specialists, resulting in confusion.

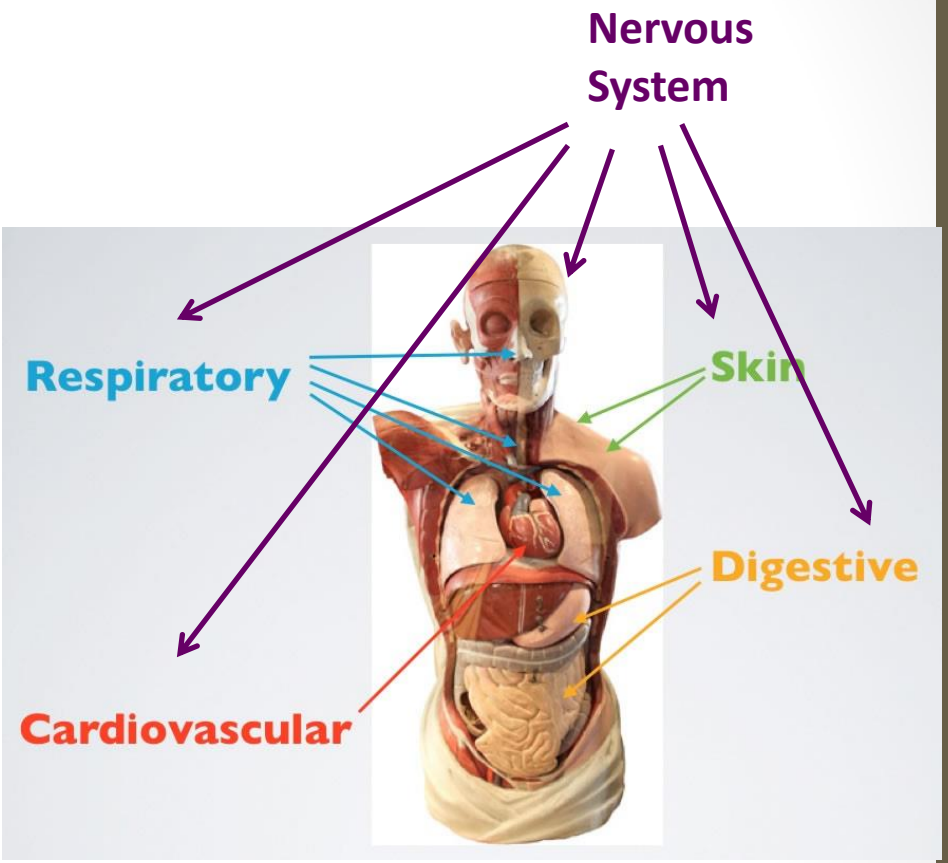

Anaphylaxis/MCAS-Signs & Symptoms

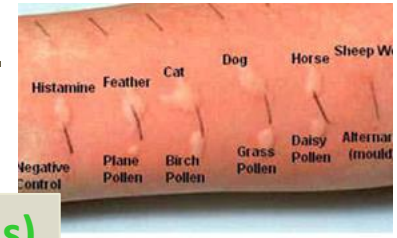

Skin Allergy Test

Skin (80-90% reactions)
Hives (urticaria)
Itch
Flushing
Mucosa
Itch, swelling –
lips, tongue, mouth)

Brain
(> 20% reactions)
Sense of uneasiness
Headache
Dizziness
Confusion
Tunnel Vision

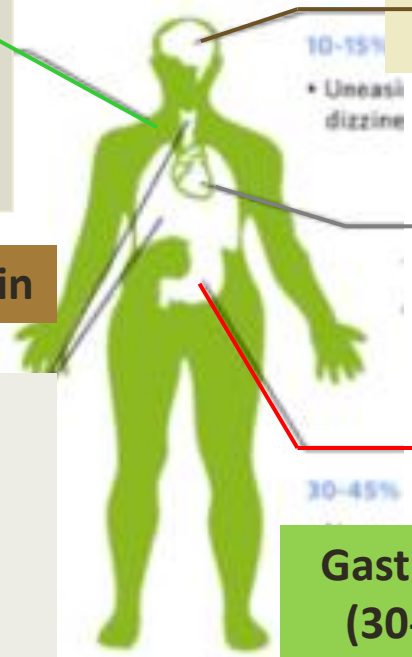

Joint/Muscle Pain

Heart, Blood Pressure
(10-45 % reactions)
Chest Pain
Fast Heart Rate,
Palpitations (pounding)
Weak pulse
Dizziness
Fainting

Airway (70% reactions)
Throat Tightening, swelling
Lungs = chest tightness,
wheeze,
can't take a deep breath

Gastrointestinal tract
(30-45% reactions)
Nausea
Cramping
Abdominal Pain
Vomiting
Diarrhea

Genito-Urinary tract
(>10% reactions)
Uterine Cramping
Swelling -labia

Diagnostic Algorithm

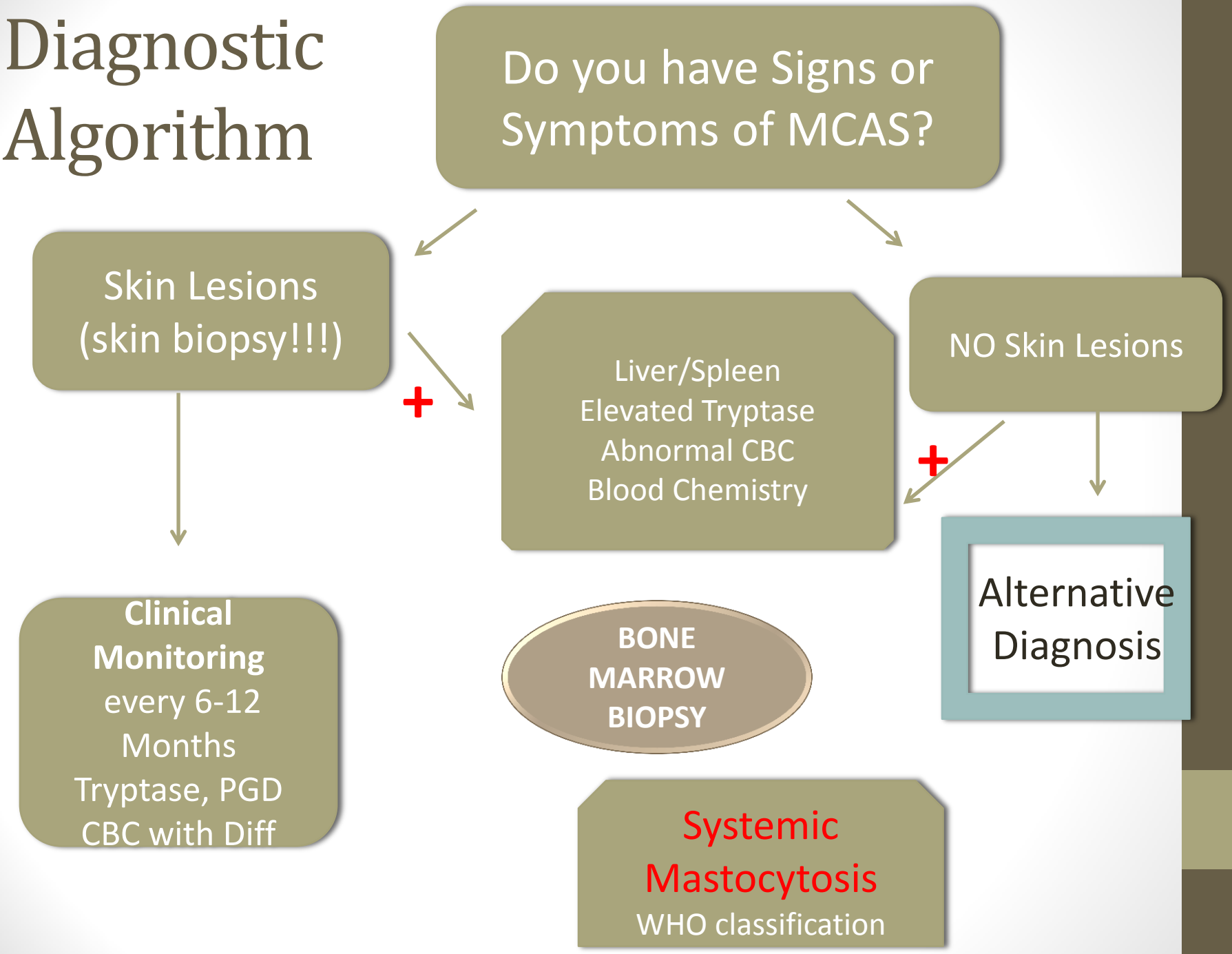

THANK YOU !

Xiu-Min Li, MD

William Reed, R-PAC

Office Staff of Comprehensive Allergy & Asthma Care and Mast Cell Center of New York